

# Multiple Pregnancy Scan - Sample Abnormal Report

## OB - Early pregnancy Scan Report

### Indication(s)

To assess fetal viability

Hypothyroid on medication

Previous Lscs

Real time B-mode ultrasonography of gravid uterus done.

Route: Transabdominal

Twin intrauterine gestation

### Type of twinning

DCDA twin spontaneously reduced to singleton

### Maternal

Cervix measured 3.2 cm in length.

Both ovaries appeared normal

### Fetus A

#### Survey

Gestational Sac seen. Sac margins appeared regular

Yolk sac seen

Fetal activity present

Cardiac activity present

Fetal heart rate - 193 bpm

#### Biometry (mm)

CRL	23.1, 9W	 (18%)
-----	----------	---

### Fetus B

#### Survey

Gestational Sac seen. Sac margins appeared regular

Yolk sac seen

Fetal activity absent

Cardiac activity absent

# Multiple Pregnancy Scan - Sample Abnormal Report

## Biometry (mm)

CRL	6.8, 6W 3D	● —   (<1%)
-----	------------	-------------

## **Impression**

DCDA twin spontaneously reduced to singleton gestation corresponding to a gestational age of 9 Weeks 3 Days

Fetus A,B - Intrauterine

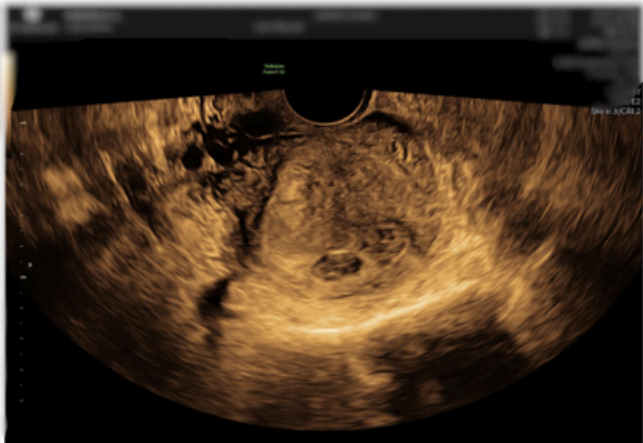
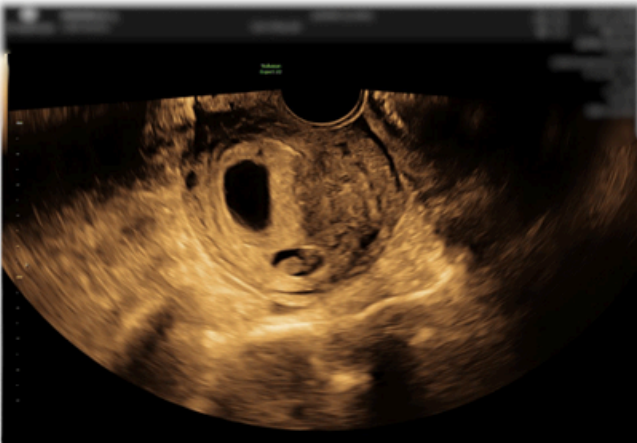
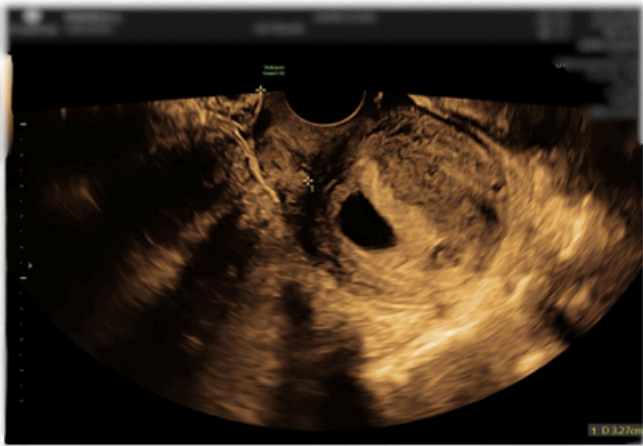
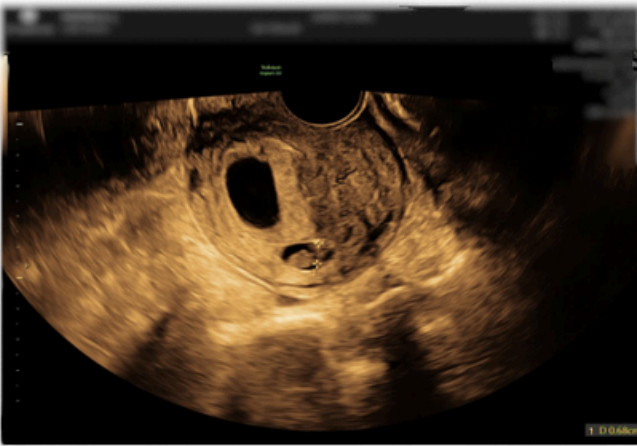
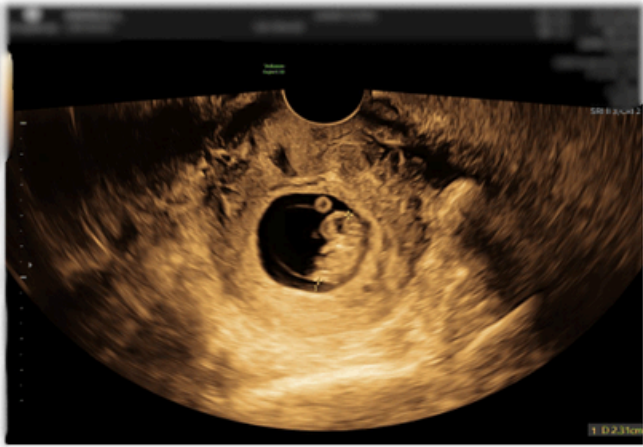
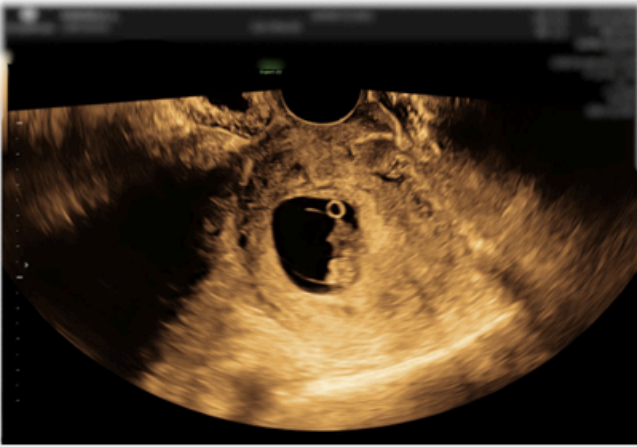
Gestational age assigned as per LMP

Twin A - Viable fetus

Twin B- Non viable fetus

Suggested repeat scan at 11-13weeks for First trimester biochemical screening on 23.02.2026

# Multiple Pregnancy Scan - Sample Abnormal Report



# Multiple Pregnancy Scan - Sample Abnormal Report

