

# Multiple Pregnancy Scan - Sample Normal Report

## OB - Early pregnancy Scan Report

### Indication(s)

To assess fetal viability

Hypothyroid on medication

Real time B-mode ultrasonography of gravid uterus done.

Route: Transvaginal

Twin intrauterine gestation

### Type of twinning

Dichorionic Diamniotic Twin

Twin Peak Sign Seen

### Maternal

Cervix measured 3.1 cm in length.

Both adnexa appeared normal

Posterior wall adenomyoma measuring 2.0x1.9cms

### Fetus A

#### Survey

Gestational Sac seen. Sac margins appeared regular

Yolk sac seen

Fetal activity present

Cardiac activity present

Fetal heart rate - 135 bpm

#### Biometry (mm)

CRL	9.3, 7W	 (72%)
-----	---------	---

### Fetus B

#### Survey

Gestational Sac seen. Sac margins appeared regular

Yolk sac seen


Fetal activity present

Cardiac activity present

Fetal heart rate - 134 bpm

# Multiple Pregnancy Scan - Sample Normal Report

## Biometry (mm)

CRL	10.3, 7W 1D	
-----	-------------	---

## Impression

Dichorionic Diamniotic Twin gestation corresponding to a gestational age of 7 Weeks

Fetus A,B - Intrauterine

Gestational age assigned by as per BT Date (17/11/2025)

Menstrual age 6 Weeks 2 Days

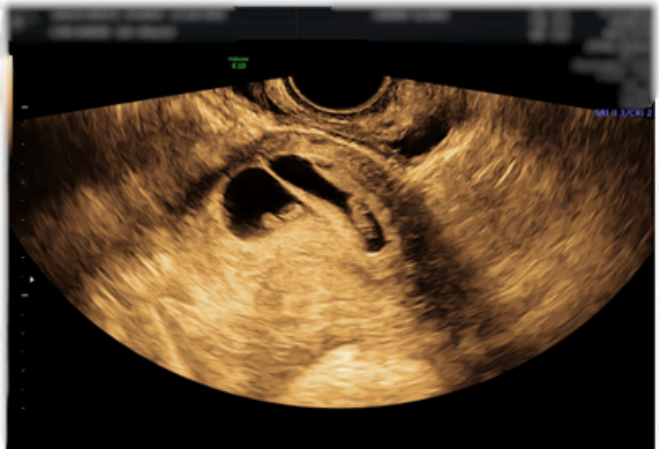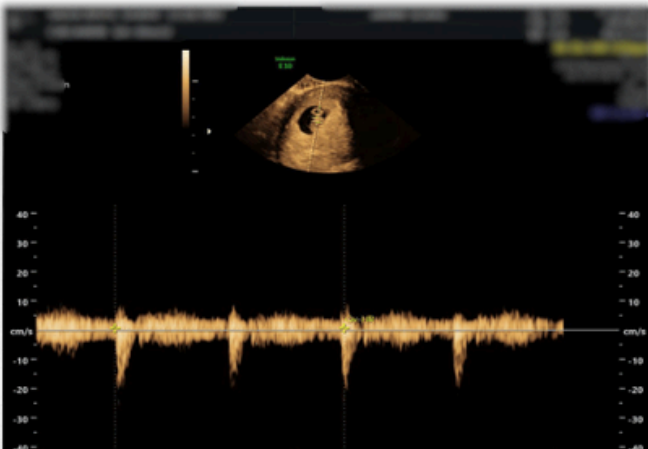
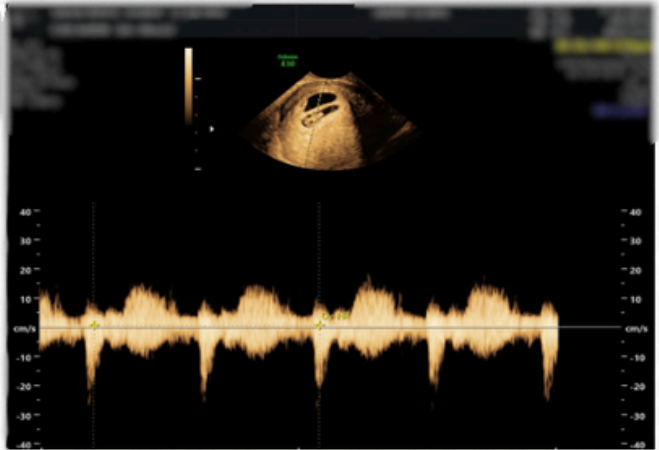
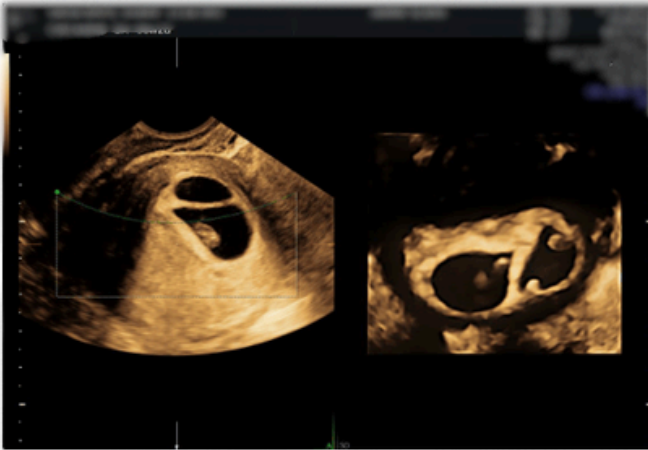
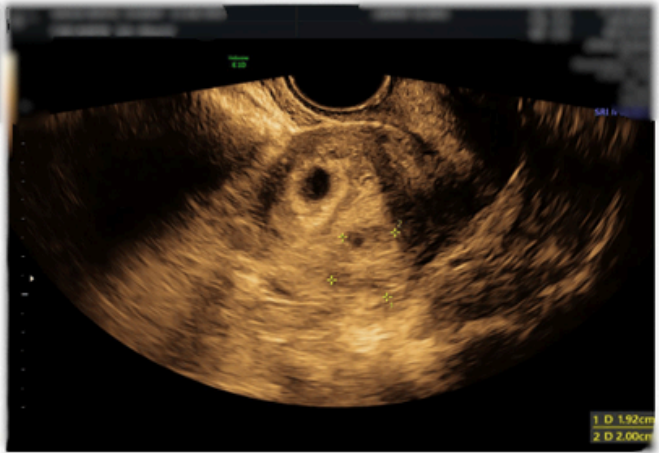
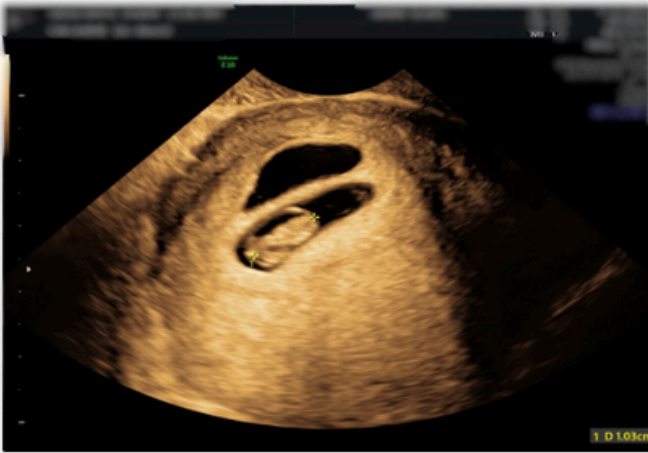EDD by BT 05/08/2026

CRL discordancy :

Fetus A - 10%

Suggested repeat scan at 11-13weeks for First trimester biochemical screening on 21.01.2026

# Multiple Pregnancy Scan - Sample Normal Report



# Multiple Pregnancy Scan - Sample Normal Report

